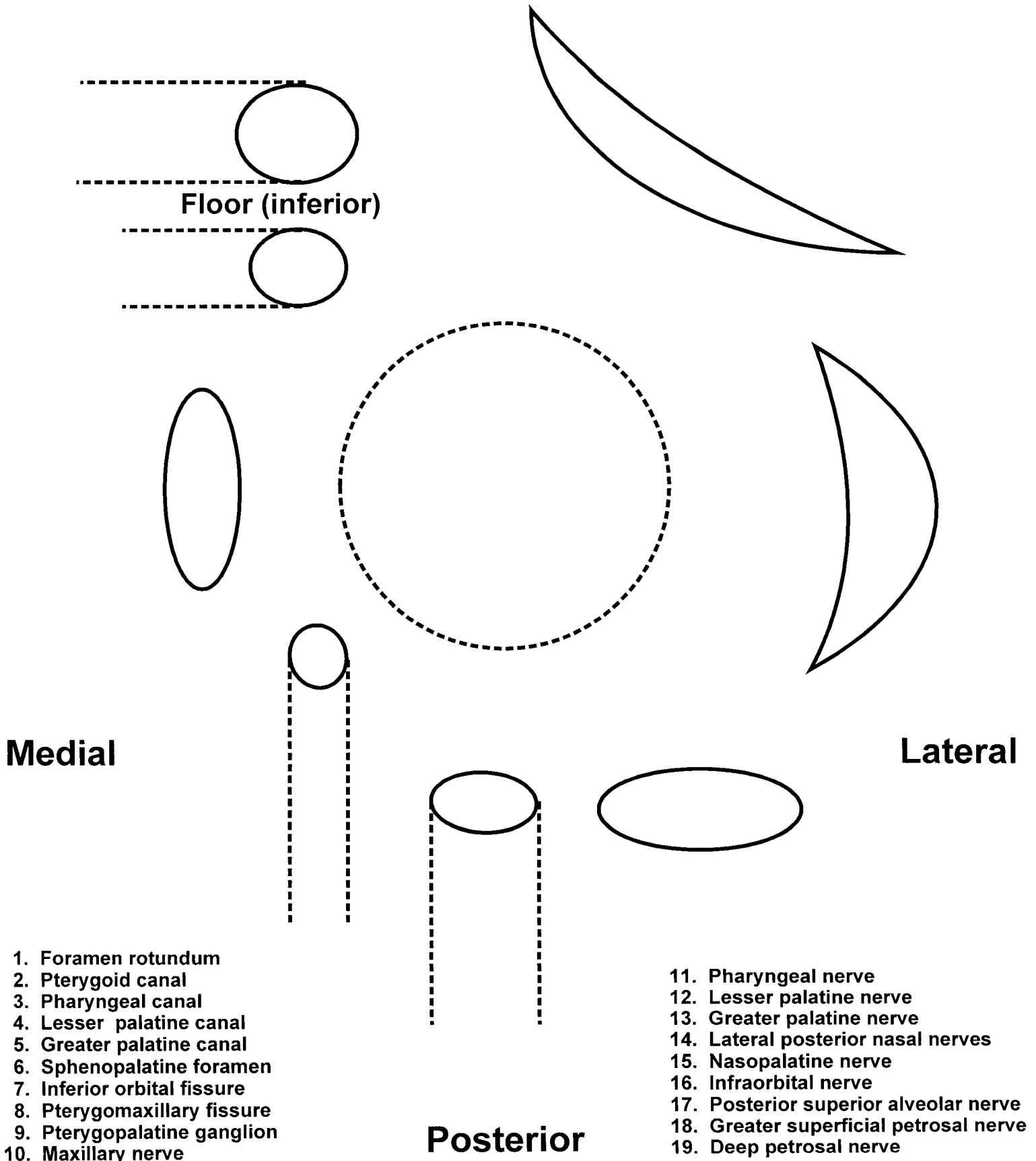
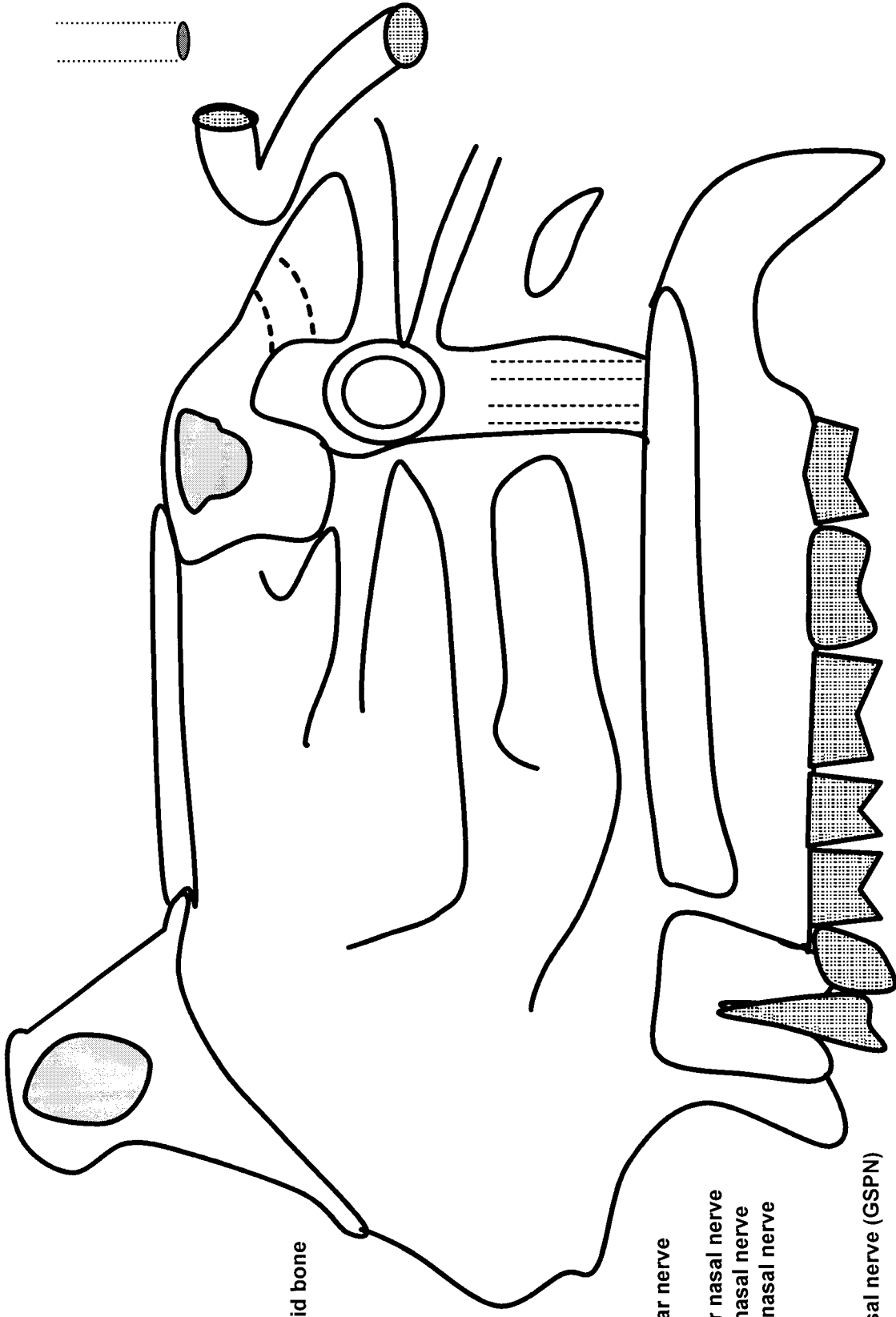


# Schematic of Pterygopalatine Fossa and Ganglion

Anterior

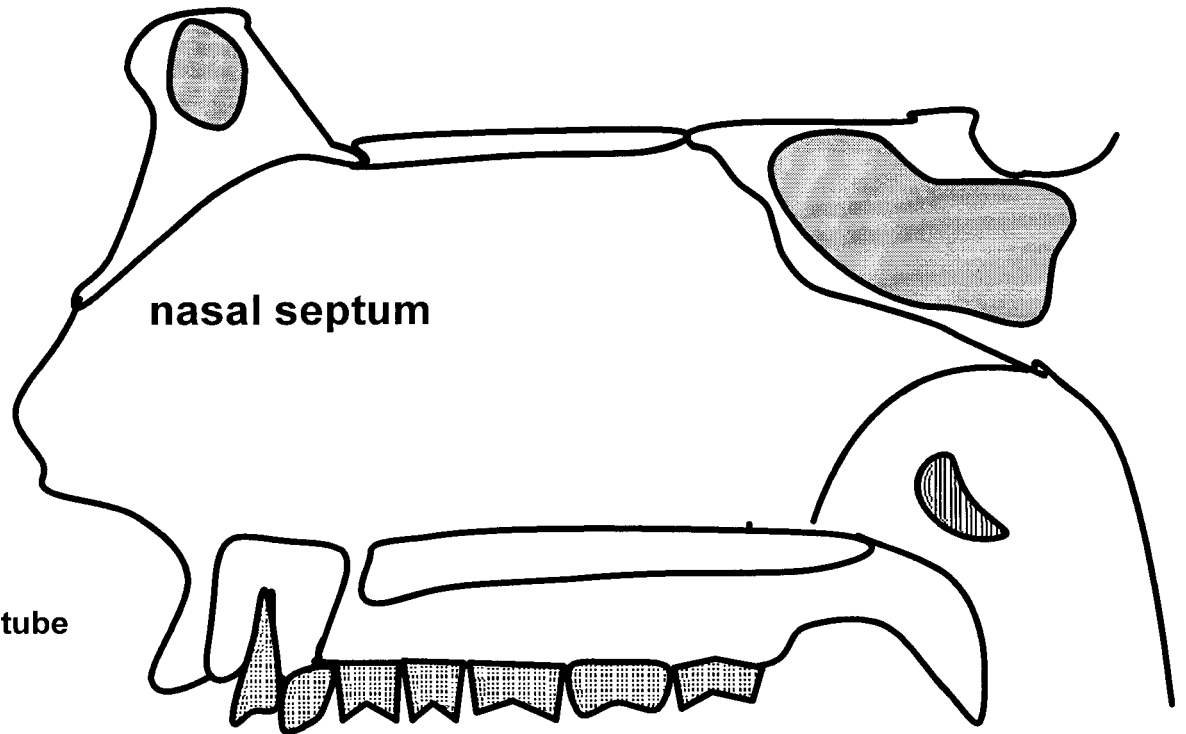


# Pterygopalatine Ganglion and Lateral Nasal Wall



1. Frontal sinus
2. Sphenoid sinus
3. Cribriform plate of ethmoid bone
4. Hard palate
5. Soft palate
6. Superior nasal concha
7. Middle nasal concha
8. Inferior nasal concha
9. Foramen rotundum
10. Pterygoid canal
11. Pharyngeal canal
12. Lesser palatine canal
13. Greater palatine canal
14. Sphenopalatine foramen
15. Pterygomaxillary fissure
16. Maxillary nerve
17. Posterior superior alveolar nerve
18. Infraorbital nerve
19. Lateral posterior superior nasal nerve
20. Lateral posterior middle nasal nerve
21. Lateral posterior inferior nasal nerve
22. Greater palatine nerve
23. Lesser palatine nerve
24. Pharyngeal nerve
25. Greater superficial petrosal nerve (GSPN)
26. Hiatus of the canal GSPN
27. Pterygopalatine ganglion
28. Internal carotid artery
29. Internal carotid plexus
30. Deep petrosal nerve
31. Nerve of pterygoid canal (Vidian)
32. Anterior ethmoidal nerve and artery
33. Internal nasal nerve
34. External nasal nerve
35. Ostium of auditory tube

# Trigeminal Nerve Branches Nasal Septum and Orbit



1. Frontal sinus
2. Sphenoid sinus
3. Ostium of auditory tube
4. Incisive canal
5. Nasopalatine nerve
6. Optic canal
7. Superior orbital fissure
8. Inferior orbital fissure
9. Infraorbital groove
10. Infraorbital canal
11. Infraorbital foramen
12. Lacrimal gland
13. Lacrimal nerve
14. Infraorbital nerve
15. Zygomatic nerve
16. Zygomaticotemporal nerve
17. Zygomaticofacial nerve
18. Communicating branch (parasympathetics)

